



# A Novel Technique to Detect Macular Edema Based on Motion Patterns

Arun Kumar.S<sup>1</sup> , Lakshmiprabha.N<sup>2</sup> , N. Stalin<sup>3</sup>

M.E (Communication Systems), Dhanalakshmi Srinivasan Engg. College , Research Scholar,  
Anna University, 1

Chennai , Department of Petrochemical technology, Anna University of Technology, BIT  
Campus, Trichy 2 3

arunkumar736@yahoo.com , laksh\_abi@rediffmail.com , [mnstalin@gmail.com](mailto:mnstalin@gmail.com)

**ABSTRACT-** In this paper a two-stage methodology for the detections and classification of Diabetic Macular Edema severity from color fundus image is proposed. DME detection is carried out via a supervised learning approach using the normal fundus images. A feature extraction technique is introduced to capture the global characteristics of the fundus images and discriminate the normal from DME image. Disease severity is assessed using a rotational asymmetry metric by examining the symmetry of macular region. Diabetic macular edema (DME) is an advanced symptom of diabetic retinopathy and can lead to irreversible vision loss.

**Keywords<sup>2</sup> Hard Exudates(HE), Diabetic Macular Edema (DME), Optic Disc (OD), Diabetic retinopathy (DR), Color Fundus Image(CFI),Region Of Interest (ROI).**

## 1, INTRODUCTION

Swelling in the macular region of retina which is also known as macular edema, is a complication of the eye often leading to reduced capacity of visions. Diabetic macular edema (DME) caused due to diabetes is a high risk complication which can cause irreversible loss of vision[1]-[3]. Early detection of even a minor sign of DME is essential as it may also appear without any external symptoms[4]. Once detected during retinal examination, it demands immediate treatment ranging from glycemic and blood pressure controls, to laser surgery. DME is generally detected directly or indirectly. Direct ways are using stereoscopy (for manual examination) or optical computed tomography images[3]. Indirect method is by detecting the presence of hard exudates (HE) in the retina. HE are formed due to secretions of plasma from capillaries resulting from the complications of retinal vasculature and could lead to retinal swelling. In color fundus images they appear as yellow±white deposits. Detecting the presence of hard exudates (HE) in different areas of retina is now considered a standard methods to assess DME from color fundus images[1],[4],[5]. The severity of the risks of edema is evaluated based on the proximity of HE to the macula, which is define to be a circular region center at fovea and with one optic disc (OD) diameter (Fig.1).The risk for DME increases when the HE locations approach the macula, with the risk being the highest when they are within the macula. This is a important factor in DME assessment for further referral



of the patients to an expert. Diabetes can also cause other retinal complications all of which are collectively termed as diabetic retinopathy (DR). Given the potential for vision loss and blindness due to DR, screening program have been launched in many countries and color fundus images forms the basis for manual assessment in screening. Such manual assessment however is not scalable in large-scale screening scenario, particularly in developing country either due to the scarcity of skilled manpower or unavailability of high end imaging equipment at the point of care. Solutions such as telescreening using permanent and mobile units to enable screening of retinal disorders in remote areas have been proposed[6],[7]. In such a scenario, an automatic disease detection systems can significantly reduce the load of expert by limiting the referrals to those cases that require immediate attention. The reductions in time and effort will be significant where a majority of patients screened for diseases turn out to be normals. Diabetic retinopathy (DR) is a progressive eye disease that currently affects 250 million of people worldwide. Diabetic macular edema (DME) is a complication of DR and it is a common cause of vision loss and blindness. DME occurs from swelling of the retina in diabetic patients due to leaking of fluid from micro aneurysms within the macula. Ophthalmologist can infer the presence of the fluid that cause the retina thickening in diabetic patients by the presence of accompanying lipid deposit called exudates. They appear as bright structures with very well defined edges and with variable shapes. The approaches to the amount of exudate segmentation presented in the very literature can be roughly divided into four different category.

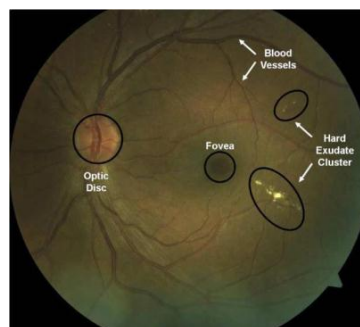


Fig.1. Color fundus images with anatomical structures

Thresholding methods base the exudate identifications on a global or adaptive grey level analysis[8],[9]. Region growing methods segment the images using the special contiguity of grey levels; a standard region growing approach is used in which is computationally expensive. In the computational issues are reduced employing edge detection to limit the size of regions. Morphology methods [14] employ gray scale morphological operators to identify all structures with predictable shapes (such as vessels). These structures are removed from the image so that



exudates can be identified Classification methods build a feature vector for each pixel or pixel cluster, which are then classified by employing a machine learning approach into exudate or not exudate or additional types of bright lesions An automated system can significantly decrease the manual labour involved in diagnosing large quantities retinal images. While this represents an obvious and significant gain, there is a larger, logistical need for automated and immediate diagnoses in rural settings: patients in rural areas are fundamentally harder to reach than in urban environments.¶ In the mobile hospital setting, if a patient comes for the morning session, there is no guarantee that the same

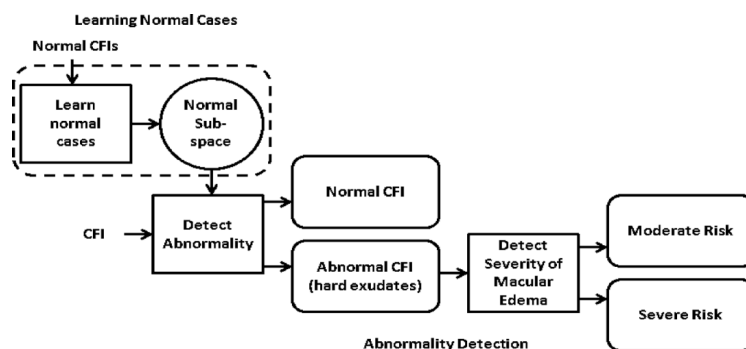


Fig.2. Processing pipeline for detection of DME

patient will return for the afternoon session unless the need for continue diagnosis is demonstrated. Consequently, if a patient actually has diabetic retinopathy, it is essential to convey the urgency of the situation to the patient as soon as a diagnosis can be reached in order to convince them to traveling to a hospital for full treatment. This is a fundamental health care delivery problem in many rural developing regions. With an automated system, the doctor or local health worker can be made aware of the diabetics retinopathy problem during a single session with a patient. This enables the medical personnel to immediately and visually demonstrate the existing problem to the patient which make it easier to convince them of the urgency of their situations. They can also immediately schedule appointments for the patients without further delay for continued diagnosis and follow-up visits at a regular hospital. An automated system also helps local health workers to detect serious diabetic retinopathy cases without the need for local ophthalmology experts.

## 2, Related Work

Among recent approach to direct detection of edema from color fundus images, multiple un calibrated fundus images have been used to estimate a height map of macula. The estimated height smap is generally noisy. A difference in the mean height is demonstrated between the height maps of normal and edema cases on synthetic images and only four sets of color fundus images. This difference is used to determine normal and abnormal cases. While the proposed method is



encouraging, it requires more rigorous validation. Using monocular color fundus image for detecting DME indirectly is still considered a reliable method in DR screening. Detecting DME is also done indirectly by detecting the presence of HE in images [5].

## 2.1 Region Of Interest Extraction

Since the severity of DME is determined based on the location of HE clusters relative to the macula, the images acquired for DME detection usually focus around the macular region. We find the best fit circle within the fundus mask [12] with macula at the center, for a given image. The region within this circle is the desired ROI denoted as The green channel of forms the input for all subsequent processing. The center of macula is automatically detected using and restricting the search to a central region of the given image since the acquired images for DME detection are maculacentric. Since the OD shares a brightness characteristic similar to HE, it is also automatically detected and masked using .The result of macula and optic disc detection can be seen in where the macula is shown as a circular patch and the OD is shown as a rectangular patch.

## 2.2 Generation Of Motion Patterns

The creation of a motion pattern is motivated by the effect of motion on biological/computer visual system. These systems represent a scene as a set of spatially sampled (by the sensors/detectors) intensities or an image. This sampling is uniform in cameras while it is log polar in human eyes. When an object in a scene moves at a high speed, it usually leaves a smearing pattern in the captured image. Fig. 3.Graphical depiction of motion pattern generation.

A motion pattern for is derived as follows where denotes a pixel location, is a transformation representing the induced motion which is assumed to be rigid than existing one. Practically speaking, generates transformed images which are combined using to coalesce the sampled intensities at each pixel location. Here, is expressed as follows where is a rotation matrix. The rotation angle with denotes the rotation step. When we have no rotation and hence . Thus is a set of rotated versions of the given and the total number of rotated images .The sampling rate of the detector determines the number of images generated in the set. In the problem at hand, since HE appear as bright localized lesions against the retinal background, they should form a bright smear pattern in whereas the textured background will be smoothed out. This representation can thus spatially enhance the characteristics of HE and help improve their detectability. At the same time, this should also serve to minimize the effect of the variability observed across images by smoothing them out. Since, the severity of the disease is directly related to the radial distance of HE in the circular ROI, rotational motion is induced to generate the desired . The transformation function is applied to generate

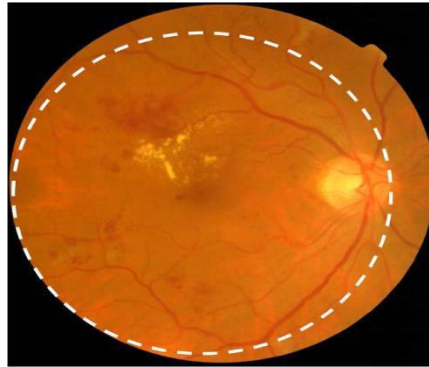


Fig. 4. Sample fundus image and the circular region of interest centered on macula.

### 2.3 Abnormality Detection:

Learning Normal Class is achieved using single class classification. In this approach, a classification boundary is formed in the feature space around the subspace corresponding to normal cases. If a new image, when transformed to this feature space, lies within this boundary, then it is classified as normal and abnormal otherwise.

### 2.4 Determining The Severity Of Macular Edema:

Assessment of the severity of macular edema is the next task. Here, the macular region which is the circular ROI within 1 optic disc diameter from the center, is of key interest as any HE within this region indicates high risk for DME, requiring immediate attention. The macula in a normal image is relatively darker than other regions in the fundus image and is characterized by (rough) rotational symmetry. We use this symmetry information to establish the risk of exhibiting edema: good degree of symmetry is taken to indicate the abnormality is not inside macula and hence it is declared as a moderate case. Asymmetry of the macula on the other hand implies abnormality is within the macula and hence the case is deemed severe. HE appear as clusters of bright, high contrast lesions and are usually well localized. The macula is a dark structure roughly at the center of the retina and causes the vision loss.



### 3, Proposed Work

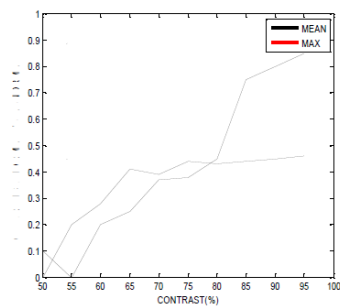
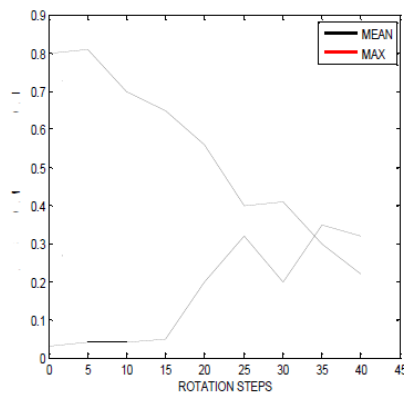
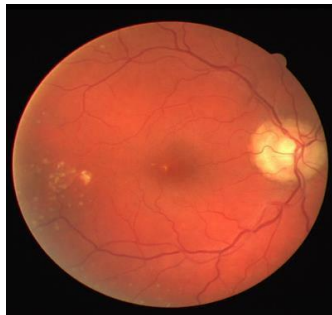In image processing, a Gabor filter is a linear filter used for edge detection. Frequency and orientation representations of Gabor filters are similar to those of the human visual system, and they have been found to be particularly appropriate for texture representation and discrimination. In the spatial domain, a 2D Gabor filter is a Gaussian kernel function modulated by a sinusoidal plane wave. The Gabor filters are self-similar: all filters can be generated from one mother wavelet by dilation and rotation. Its impulse response is defined by a harmonic function multiplied by a Gaussian function. Because of the multiplication-convolution property (Convolution theorem), the Fourier transform of a Gabor filter's impulse response is the convolution of the Fourier transform of the harmonic function and the Fourier transform of the Gaussian function. The filter has a real and an imaginary component representing orthogonal directions. [2] The two components may be formed into a complex number or used individually. The 40 wavelets which have been created from indices  $\theta \in [0, 2\pi)$  (size) and  $\sigma \in [0, 2\pi)$  (orientation) are shown below. These wavelets are convolved with the image, and we keep the value of the center pixel. This provides us with a feature vector of 80 complex coefficients, but we only keep the amplitudes for classification. Since the severity of DME is determined based on the location of HE clusters relative to the macula, the images acquired for DME detection usually focus around the macular region. We find the best fit circle within the fundus mask with macula at the center, for a given image. The region within this circle is the desired ROI. The green channel of forms the input for all subsequent processing. The center of macula is automatically detected using and restricting the search to a central region of the given image since the acquired images for DME detection are macula-centric. Since the OD shares a brightness characteristic similar to HE, it is also automatically detected and masked using . The result of macula and optic disc detection can be seen in Fig. 4 where the macula is shown

as a circular patch and the OD is shown as a rectangular patch. Our strategy for detecting macular edema and evaluating its severity is as follows: The image under evaluation is first ascertained to be normal (abnormality detection) by learning the characteristics of normal retinal images. Any deviation from normal characteristics is taken to be indicative of abnormality. For every abnormal image the severity of DME is assessed by determining the location of HE relative to the macula. The Gabor filters are very useful in the edge detection, corner detection and blob detection. These filters hence produce the filter output which is relating by the equations specified above concerning the Gabor wavelets. Then the feature extraction process is made and the various factors have been find out. Using these factors we concludes whether the given retina has moderate or severe risk. Assessing the severity of macular edema is the next task. Here, the macular region which is the circular ROI within 1 optic disc diameter from the center, is of key interest as any HE within this region indicates high risk for DME, requiring immediate attention. The macula in a normal image is relatively darker than other regions in the fundus image and is characterized by (rough) rotational symmetry. We use this symmetry information to establish the risk of exhibiting edema: good degree of symmetry is taken to indicate the abnormality is not inside macula and this leads to vision loss.



## 4, Simulation Results

### A. Existing System



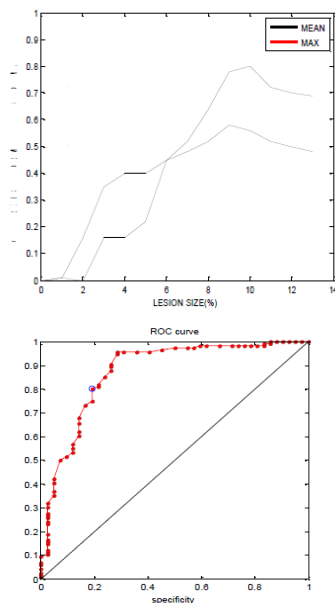


Fig.5. a) retina with hard exudates b) Effect of rotation step versus normal and abnormal retinal images c) Effect of contrast versus normal and abnormal retinal images d) Effect of lesion size versus normal and abnormal retinal images e) ROC Curve

## B. Proposed System





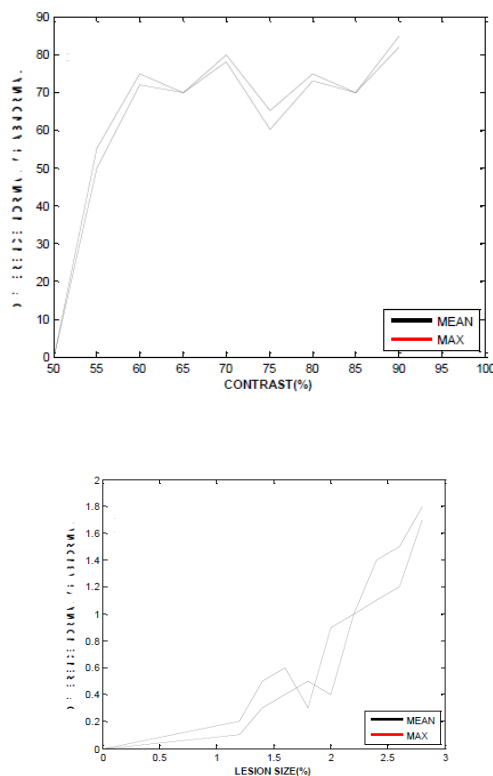


Fig.6. a) Gabor Wavelet features b) Effect of contrast versus normal and abnormal retinal images c) Effect of lesion size versus normal and abnormal retinal images

## 5, CONCLUSION

A supervised technique based on learning the image characteristics of only normal patients is used for detecting the abnormal cases pertaining to HE. This approach has the inherent advantage of reducing the effort of building a CAD system by removing the need for annotated (at the lesion level) abnormal images. Such annotations are required for both supervised and unsupervised classification schemes in order to find suitable system parameters for detection. This is due to the proposed global features. The proposed method is shown to be effective in detecting DME for challenging cases we can observe that HE manifest as faint lesions whereas in faint HE can be seen over a complex background. In the second level, the severity of the abnormality is assessed by analyzing the rotational asymmetry of the macular region in retina. This level facilitates the



decision to recommend a patient to a medical expert, based on the proximity of HE to the center of macula

### Acknowledgment

I wish to acknowledge Lakshmiprabha.N and other contributors for the support of completion of my files which have been used in the preparation of this template. I wish to acknowledge Aravind Eye Hospitals for the supply of retinal images of various diabetic macular edema patients which helped me to work with real time images for the completion of this work.

### REFERENCES

- [1] L. Giancardo, F. Meriaudeau, T. P. Karnowski, Y. Li, K. W. 7 RELQ\_ -U\_\_ DQG (\_ &KDXP\_\_\_\_\_ <sup>3</sup>*Automatic Retina Exudates Segmentation Without A Manually Labelled Training Set\_* LQ Proc. 2011 IEEE Int. Symp. Biomed. Imag: From Nano to Macro, , pp. 1396±1400.
- [2] C. P. Wilkinson, F. L. Ferris, R. E. Klein, P. P. Lee, C. D. Agardh, M. Davis, D. Dills, A. Kampik, R. Pararajasegaram, and  
- \_ 7 \_ 9HUGDJXHU\_\_\_\_\_ <sup>3</sup>*Proposed International Clinical Diabetic Retinopathy And Diabetic Macular Edema Disease Severity Scales\_* Am. Acad. Ophthalmol., vol. 110, no. 9, pp. 1677±1682,
- [3] R. F. N. Silberman, K. Ahlrich, and L. Subramanian, (2010) <sup>3</sup>&DVH )RU AXWRPDWHG 'HWHFWLRQ 2I 'LDEHWLF 5HWLQRSDWK\,AAAI Artif. Intell. Development (AI-'\_ , pp. 85±90,
- [4] T. Walter, J.-&\_ .OHLQ\_ 3\_ 0DVVLQ\_ DQG \$\_ (UJLQD\ \_\_\_\_\_ <sup>3</sup>*A Contributions Of Image Processing To The Diagnosis Of Diabetic*